

Chitosan improves the *in vivo* biological response to soy-based biomaterials

A. P. Marques^{1,2}, T. C. Santos^{1,2}, R. M. P. da Silva^{1,2}, S. S. Silva^{1,2}, J. M. Oliveira^{1,2}, M. van Griensven³, J. Mano, H. Redl³, R. L. Reis^{1,2}

¹3Bs Research Group-Biomaterials, Biodegradables and Biomimetics, Univ. of Minho, Campus de Gualtar, 4710-057 Braga, Portugal

²IBB – Institute for Biotechnology and Bioengineering, PT Government Associated Laboratory, Braga, Portugal

³Ludwig Boltzmann Institute for Experimental and Clinical Traumatology, Donaueschingenstrasse 13, A-1200 Vienna, Austria

Statement of Purpose: Natural-origin biomaterials have shown to trigger adequate biological responses within a wide range of applications. Nonetheless, there is still a lack of *in vivo* studies for materials such as soybean in the literature. This study was designed to test the outcome of the injection of chitosan and soybean protein isolate (SI) powders, and of the implantation of SI and chitosan/soy (cht/soy) based membranes in rats ultimately to be used as wound dressings.

Materials & Methods: The tested materials were: powders of i) soybean protein isolate (SI-P) and ii) chitosan (cht-P); and membranes of iii) soybean protein isolate (SI-M) and chitosan/soy (cht/soy-M). Phosphate buffer saline (PBS) suspensions of the powders with different concentrations (0.1% and 1% SI; and 0.1%, 1% and 2% chitosan) were injected into the intraperitoneal (IP) cavity of the rats (1 mL per animal). Three animals per concentration and for each time period (16 hours, 3 days, 7 days and 15 days) were used. One animal per each concentration and per each time period was injected with sterile PBS as control. After the pre-determined post-injection periods, cytological analysis of the intraperitoneal inflammatory exudates was performed.

For the subcutaneous (SC) implantation of the SI membranes, Wistar Han rats were used. A full thickness skin longitudinal incision (about 1.5 cm), was performed in each animal, and one cranial oriented subcutaneous pocket was created by blunt dissection. The SI membranes were positioned in the pockets, and the incisions were carefully sutured. For the SC implantation of cht/soy membranes, male Sprague-Dawley rats were used. Two medial skin incisions were performed on the dorsum of the rats and two craniolateral oriented pockets were subcutaneously created by blunt dissection where the membranes were inserted (4 membranes/animal). All animals were kept with food and water *ad libitum* during all observation time. The subcutaneously implanted samples were explanted with the surrounding tissue, on days 3, 7, 15 and 30 for SI-M and 7 and 15 for cht/soy-M, for histological analysis.

Results: In terms of inflammatory cell recruitment to the intraperitoneal cavity after the IP implantation of SI-P and cht-P, the results showed normal cell recruitment at all times of implantation and for all the tested powder concentrations. Polymorphonuclear neutrophils (PMNs) were the earliest recruited cells; higher number of PMNs, in comparison with the control, was detected after SI-P injection however, normal values were restored after day 7. PMNs were followed by mononuclear cells (macrophages and lymphocytes) which, remained at constant levels for all the conditions. SI-P induced higher

recruitment of lymphocytes and were maintained at significantly higher levels than the control 15 days post-injection of 1% of SI-P. In what concerns eosinophils and mast cells recruitment, typically related with allergic reactions, the higher levels of mast cells detected after 0.1% SI-P injection diminished along the time of the experiment to values similar to the control.

The SC implantation of SI-M induced a severe inflammatory reaction at all times of implantation, conversely to cht/soy-M. Significant necrosis of the abundant granulocytic infiltrate was observed and maintained along the implantation period (Figure 1A). Although the implantation periods of cht/soy-M were only 1 and 2 weeks, it was clear that the induced inflammatory response corresponds to a normal implantation reaction with almost no foreign body giant cells formation and a normal recruitment of inflammatory cells (Figure 1B).

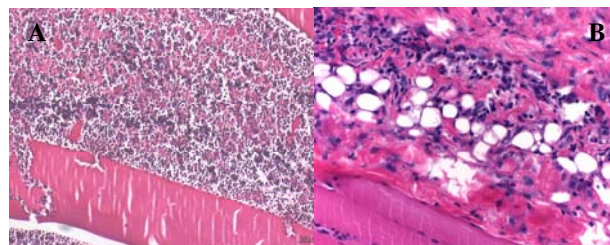


Figure 1. Hematoxylin and Eosin staining of SI-M (A) and cht/soy-M (B) respectively after 15 and 7 days of subcutaneous implantation.

Conclusions: Despite the leukocyte kinetics which has only revealed a significant presence of lymphocytes after injection of 1% SI-P, soybean materials have demonstrated a high inflammatory potential when subcutaneously implanted in rats. Nevertheless, the combination of SI with chitosan, in the cht/soy membranes, impaired the reaction of the surrounding tissue leading to a normal inflammatory process, thus demonstrating the prospective of these membranes for application in the biomedical field.

Acknowledgments

This work was partially supported by the European Union funded STREP Project HIPPOCRATES (NMP3-CT-2003-505758) and Alea Jacta EST (MEST-CT-2004-008104) – Marie Curie Early Research Training Programme, and was carried out under the scope of the European NoE EXPERTISSUES (NMP3-CT-2004-500283).